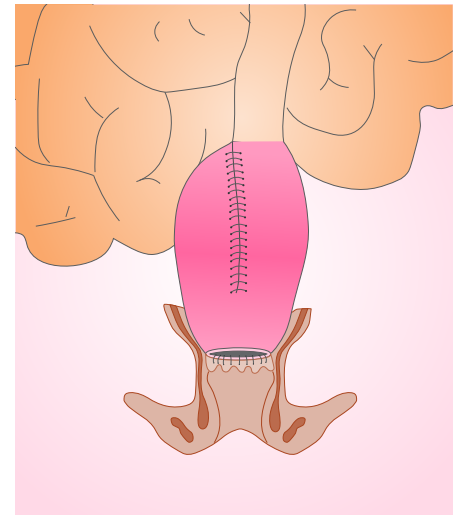


Mistakes in pouchitis and how to avoid them

Jonathan P Segal, Susan K Clark and Ailsa L Hart

Restorative proctocolectomy can be considered a quality-of-life surgical procedure for patients who have ulcerative colitis that has not responded to medical therapy, and for some patients who have familial adenomatous polyposis. The procedure removes the entire diseased large bowel and utilises the patient's small bowel to create a reservoir that allows defaecation without the need for a long-term ileostomy. Despite generally good outcomes, complications can occur. One of the most frequent problems is primary idiopathic pouchitis, which is characterized by increased stool frequency, haematochezia, abdominal cramping, urgency, tenesmus, incontinence, fever and flare-up of extraintestinal manifestations.¹ The incidence of acute primary idiopathic pouchitis following surgery has been reported to be 20% at 1 year, and up to 40% at 5 years.² Chronic primary idiopathic pouchitis develops in 10–15% of all patients who undergo restorative proctocolectomy for ulcerative colitis and can be 'responsive' or 'refractory' to antibiotic therapy. Chronic pouchitis is defined as symptoms of pouchitis that persist beyond 4 weeks or multiple relapses of acute pouchitis within a year.^{3,4} Here we discuss mistakes in the assessment and management of primary idiopathic pouchitis and how best to avoid them. Most of the discussion is evidenced based, but where evidence is lacking the discussion is based on our extensive clinical experience of treating patients who have pouch dysfunction.



Mistake 1 | Assuming all pouch dysfunction is primary idiopathic pouchitis without excluding alternative diagnoses

There are no validated scoring systems available to define pouchitis. The pouch disease activity index (PDAI)⁵ is used in the research setting but it remains unvalidated and its routine use in clinical practice is rare.

Importantly, there can be a lack of correlation between symptoms, endoscopic activity and histological findings, leading to potential misdiagnosis.^{6,7} Furthermore, there is a tendency to label every patient who has pouch dysfunction as having pouchitis; primary idiopathic pouchitis is often diagnosed without endoscopic and histological confirmation, which can result in other pathologies being missed. In addition, patients often self-diagnose primary idiopathic pouchitis based on their symptoms, without objective markers of inflammation or endoscopic assessment being used.

It is also important to distinguish between primary and secondary types of pouchitis. Primary idiopathic pouchitis is defined as pouchitis when all secondary causes have been excluded, whereas secondary pouchitis can be due to Crohn's disease, infection (e.g. with *Clostridioides* [formerly *Clostridium*] *difficile*,

Campylobacter, *Salmonella*, *Candida* or cytomegalovirus), pelvic sepsis, faecal stasis, ischaemia or drugs (particularly NSAIDs).⁸

When patients present with symptoms related to their pouch it is important to be mindful that other possible causes (e.g. hyperthyroidism, coeliac disease or pouch cancer) are excluded. This is best done by following an algorithm, such as the one presented in figure 1.⁹

It is essential to take a robust history, perform a thorough examination and offer timely investigations (including pouchoscopy and radiological examination) before confirming a diagnosis of primary idiopathic pouchitis. An important question to ask is "Has the pouch ever worked well?" If this is not the case, a diagnosis of anastomotic leak/pelvic sepsis needs careful consideration. Importantly, it is essential to establish the baseline pouch function for an individual patient; the median 24-hour stool frequency is four to eight, with roughly half of patients needing to defecate at night.

Mistake 2 | Missing pelvic sepsis as a cause of pouchitis

In one retrospective study, more than a third of patients considered to have antibiotic-dependent pouchitis were actually found to have evidence of

pelvic sepsis on MRI.⁷ It is therefore imperative to thoroughly assess a dysfunctional pouch with MRI. The potential consequences of missing this diagnosis are inappropriate use of antibiotics, antibiotic resistance, side effects and worsening clinical state. Furthermore, by missing pelvic sepsis and assuming symptoms are primary idiopathic pouchitis, there is the potential to escalate to biologics, which may cause immunosuppression and worsening sepsis. Should pelvic sepsis be found, appropriate antibiotic therapy should be considered, with a multidisciplinary discussion to plan management that may include drainage and diversion.

Mistake 3 | Not systematically assessing and reporting all pouch regions endoscopically

Thorough endoscopic assessment is vital to help understand the potential reasons for a poorly functional pouch. However, no validated endoscopic reporting systems, key performance indicators, training or certification are available to assess competency in pouchoscopy. Furthermore, there is considerable variation in the quality of endoscopy reports and efforts have only recently been made to develop a reporting template specific to pouchoscopy.¹⁰ The standardised

© (2020) Segal, Clark and Hart.

Cite this article as: Segal JP, Clark SK and Hart AL. Mistakes in pouchitis and how to avoid them. *UEG Education* 2020; 20: 7–11.

Jonathan Segal is a specialist gastroenterology registrar and Susan Clark is a consultant colorectal surgeon at St Mark's Hospital, Harrow, United Kingdom and in the Department of

Surgery and Cancer, Imperial College London, United Kingdom.

Ailsa Hart is a consultant gastroenterologist at St Mark's Hospital, Harrow, United Kingdom and in the Faculty of Medicine, Department of Metabolism, Digestion and Reproduction, Imperial College London, United Kingdom.

Illustrations: J. Shadwell.

Correspondence to: jonathansagal1@nhs.net

Conflict of interest: The authors declare they have no conflicts of interest to declare in relation to this article.

Published online: July 9, 2020.

reporting template introduced is a systematic tool that prompts examination of the anal/perineal region, rectal cuff, anastomosis, lower and upper pouch body, pouch inlet and pre-pouch ileum, but it is not widely used.

Other problems with pouchoscopy include poor intra- and inter-rater reliability between pouchitis scoring systems,¹¹ with some of the PDAI descriptors considered inappropriate for assessing endoscopic disease activity in pouchitis. This suggests that we need better validated scoring systems for assessment of pouch inflammation.¹¹

We suggest that endoscopic examination of a pouch is performed by experienced endoscopists and that a systematic template should be used to encourage examination (and biopsy) of all pouch regions and recording of findings. Photographic evidence of the pouchoscopy can also help assessment.

Mistake 4 | Failing to appreciate the impact of symptoms on quality of life

There is a large variation in how different patients perceive their pouch symptoms and how their symptoms impact on their overall quality of life (QoL). There can also be a disconnect between symptom burden and the severity of inflammation noted in the pouch. Indeed, some patients with very minimal objective inflammation noted endoscopically and histologically can have pouch function that severely impacts on their quality of life, whereas other patients can report minimal symptoms but have severe inflammation noted. It is essential to be conscious of this variability and discrepancy, so that investigation and management is tailored to the individual patient. In patients who have a high symptom burden but little inflammation, other causes of their symptoms should be explored along with all supportive options available, including psychological support.

The clinical scoring systems do not take into account QoL indicators that may be significant to a patient, which means it is vital to consider a patient's quality of life when assessing symptomatology. We recommend that a broad range of domains (including effect on personal life, work, sexuality and overall quality of life) are taken into account. To aid such assessment, a multidisciplinary team of pouch and stoma nurses, psychologists, clinicians and patient-to-patient support can be valuable when helping patients with pouch-related issues.

Specifically, it is important to assess the mental health of a patient who has poor pouch function and offer them psychological support. There has been evidence to show that adjuncts such as biofeedback may be beneficial.¹² Irritable pouch syndrome (analogous to irritable bowel syndrome) is diagnosed when no other pathology is present to explain symptoms, and may

respond to medications such as tricyclic antidepressants.

Mistake 5 | Not recognising the presence of cuffitis

When forming a pouch, there is an anastomosis between the ileal pouch and the anorectum. In some situations, this area—referred to as the cuff—can become inflamed, resulting in 'cuffitis'. Essentially this is residual ulcerative proctitis. The symptoms of cuffitis are characterised by the frequent passage of stool with small quantities of blood,¹³ urgency and pain and it can, therefore, be mistaken for pouchitis.

A digital examination should be performed to manually feel the cuff. A long retained rectal cuff (longer than 2cm) is more prone to inflammation. Endoscopic evaluation is required to directly visualise the cuff, with biopsy samples taken for histological assessment to confirm the diagnosis.^{13–15} The incidence of inflammation of the retained anorectum has not been extensively studied; some studies report a 9% incidence.¹⁶

The treatment for cuffitis differs from that for pouchitis and so distinguishing the two is key. Although cuffitis is a poorly studied condition, there is evidence that mesalamine suppositories¹⁴ may provide some benefit, with steroid suppositories as a second-line therapy.¹⁷ Essentially the management of cuffitis is the same as treating ulcerative proctitis.

Mistake 6 | Labelling the diagnosis as Crohn's disease when the features may be due to another aetiology

Prior to pouch formation a thorough pre-surgical assessment must be considered to rule out Crohn's disease, to include small-bowel studies, histological samples reviewed for the presence of granuloma and the absence of a history of perianal disease. A preoperative diagnosis of Crohn's disease of the pouch is a relative contraindication to pouch surgery¹⁸ because of the high rate of complications and pouch failure.^{19–21} Indeed, it has been estimated that pouch excision rates are 45–55% in patients who have a preoperative diagnosis of Crohn's disease^{21,22} and that the pouch retention rate 5 and 10 years after formation is 58% and 50%, respectively.²³ Despite this, some small studies have shown that in the absence of perianal or small-bowel disease, restorative proctocolectomy can be performed with similar outcomes to those who have a pouch for ulcerative colitis.^{24,25} Indeed, the European Crohn's and Colitis Organisation (ECCO) suggest that restorative proctocolectomy can be offered to patients who have Crohn's disease without perianal disease or small-bowel involvement,²⁶ but we suggest that patients are very carefully counselled about the potential

poor outcomes and such surgery is done highly selectively.

There are essentially two scenarios that lead to a diagnosis of 'Crohn's disease of the pouch'. The first arises when there has been a preoperative diagnosis of Crohn's disease, and the second is the development of Crohn's-like features after the formation of a pouch in a patient who has ulcerative colitis.

In one long-term study, 2–8% of patients who originally underwent restorative proctocolectomy for presumed ulcerative colitis had their original diagnosis changed to Crohn's disease.²¹ We believe it is important to diagnose Crohn's disease of the pouch accurately to help with prognostication and offer appropriate treatment. The criteria utilised to diagnose Crohn's disease are varied. Some studies have defined Crohn's disease of the pouch as including: inflammation of the pouch that is resistant to antibiotic treatment, stricturing of the afferent limb, stricturing of the small bowel, or fistulating disease.^{27–30} Furthermore, the presence of pre-pouch ileitis is controversial—some studies suggest this may be an endoscopic feature of Crohn's disease,^{31,32} but this has been disputed by others.³³

It is likely that Crohn's disease of the pouch is an overused diagnosis, with one study highlighting that histological confirmation of Crohn's disease was found in only 20% of patients who underwent pouch excision for Crohn's disease of the pouch.³³ It is also important to appreciate that strictures and fistulas that may mimic Crohn's disease can be caused by other factors such as sepsis, anastomotic complications (e.g. leak and/or stricture) or ischaemia. We therefore suggest that Crohn's disease of the pouch should only be diagnosed by conclusive histology (i.e. granulomas supporting Crohn's disease) and/or the presence of characteristic skip lesions in the small bowel. The timing of when the Crohn's-like problems of the pouch occur can often aid diagnosis—fistulas especially around the anastomosis that occur within a year of pouch formation are likely to be related to the surgery itself, whereas complications beyond this point could represent de novo Crohn's disease, but this still requires thorough investigation.

We also believe that it can be unhelpful and confusing for patients to hear that their diagnosis has changed from ulcerative colitis to Crohn's disease and suggest it is more useful to explain that they have active inflammatory bowel disease. It is more beneficial for the patient to be clear on the strategies of care for managing their problem, whether it be a fistula, stricture or inflammation, using the appropriate combination of surgical/endoscopic and medical therapies, than to become bogged down in semantics regarding terminology.

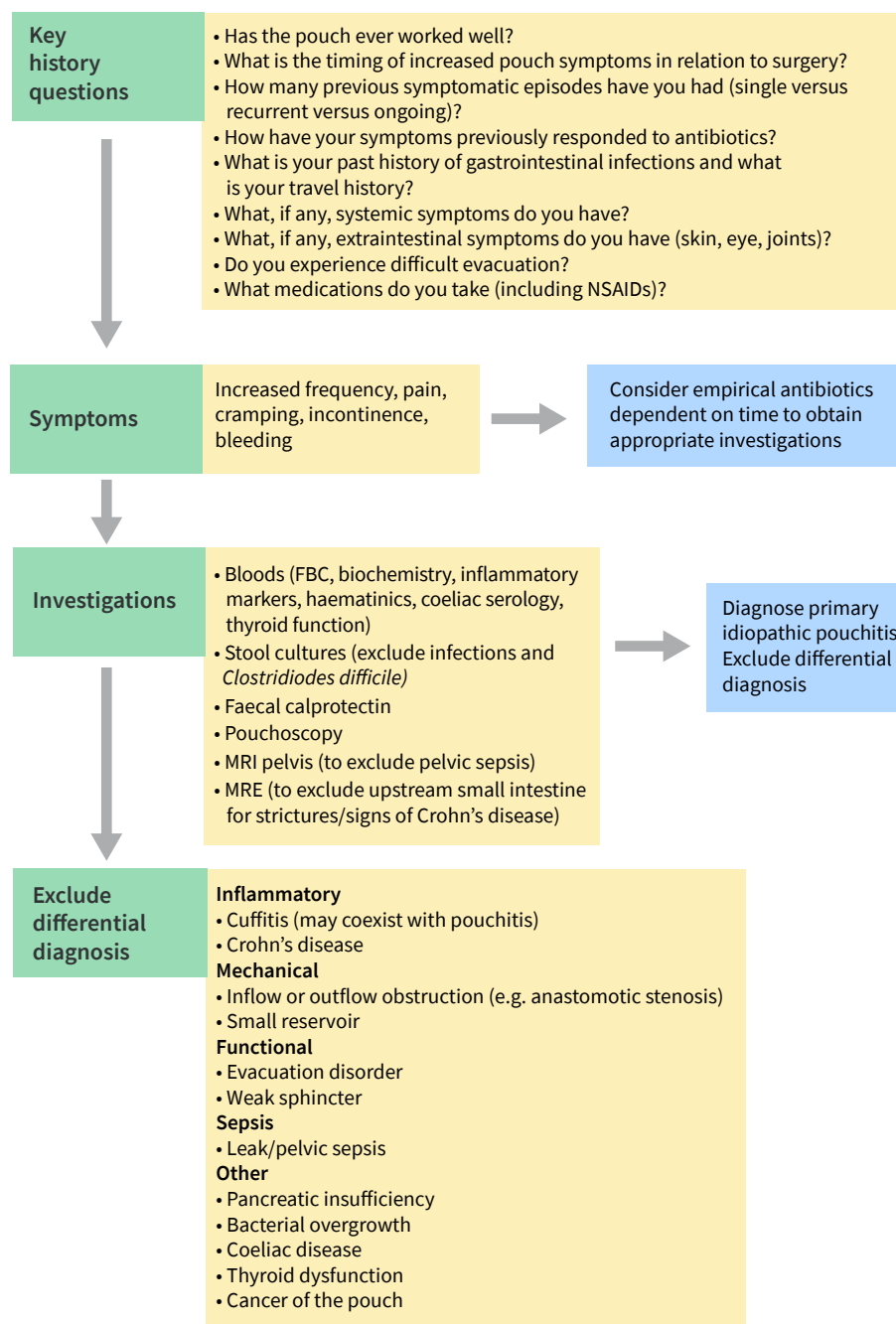


Figure 1 | Evidence-based algorithm for the diagnosis of primary idiopathic pouchitis. Adapted with permission from Segal JP, et al. *Aliment Pharmacol Ther* 2017; 45: 581–592 © (2016) John Wiley & Sons Ltd.

Mistake 7 | Failing to reassess patients regularly when they are taking long-term antibiotic treatment

Chronic primary idiopathic pouchitis develops in approximately 10–15% of patients with acute pouchitis and it can be 'responsive' or 'refractory' to antibiotic therapy.³⁴ Some of these patients require long-term antibiotics to maintain symptomatic relief.³⁴ The two antibiotics most commonly used to treat primary idiopathic pouchitis are ciprofloxacin and metronidazole. Patients should be counselled on the specific

adverse effects of these medications, which include tendinopathy in the case of ciprofloxacin³⁵ and peripheral neuropathy in the case of metronidazole (see figure 1).³⁶ In particular, patients should be made aware of the risks of long-term antibiotic use and other therapeutic options considered.

The long-term use of antibiotics can be associated with the development of antibiotic-resistant organisms.³⁴ There have been case series suggesting that *C. difficile* infection occurs in patients who have a pouch and are taking antibiotics and that they should be used

cautiously, especially in the elderly.³⁷ We advise regular reassessment of patients on long-term antibiotics, including QoL assessment, endoscopic and radiological investigations and consideration of alternative medications where appropriate. As already described, more than a third of patients considered to have antibiotic-dependent pouchitis were found to have evidence of pelvic sepsis on MRI⁷ and hence this should be excluded before a diagnosis of chronic antibiotic-dependent primary idiopathic pouchitis is made.

Mistake 8 | Commencing biologics without fully reassessing the diagnosis and patient needs

If antibiotics fail to control chronic pouchitis, biological therapies can be considered; however, sepsis must be excluded before embarking on this. Limited evidence—based on small case series and not randomised controlled trials—indicate that, overall, anti-TNF therapies are associated with a 45–58% response rate.³⁸ Anti-TNF agents were the first to show some benefit for patients with refractory pouchitis, with emerging data that ustekinumab³⁹ and vedolizumab⁴⁰ may also be effective. Non-biologic alternatives, such as alicaforsen (an antisense oligonucleotide), may be an option but formal results from a phase 3 trial have not yet been published.⁴¹

Importantly, if a patient requires biologic therapies, their symptom burden is usually quite severe and hence ongoing objective assessment of drug effectiveness and exploration of quality of life are essential. We recommend that patients are counselled thoroughly prior to starting biologics and, where possible, they have a joint consultation with an experienced pouch surgeon to discuss alternatives (pouch diversion or excision). Chronic pelvic sepsis must be excluded using cross-sectional imaging. Clear timelines must be discussed with the patient when planning a strategy of care, so that if biologic drugs do not achieve the predetermined goals set with the patient, alternative options are sought.

Mistake 9 | Failing to optimise diet and fluid intake

As for all forms of IBD, validated, robust and consistent data on which to base dietary advice for patients with pouchitis are lacking. There is evidence that fruit consumption can reduce the incidence of primary idiopathic pouchitis⁴² and a reduction of foods rich in antioxidants can predispose to pouchitis.⁴³

In terms of vitamin deficiencies, it has been highlighted that of patients who have undergone restorative proctocolectomy, 10.6% have a vitamin D deficiency and 5% have either

a vitamin A or B12 deficiency. Furthermore, patients with pouchitis may be at risk of having lower levels of calcium, total cholesterol, triglycerides, vitamin E and iron.^{44,45} It is therefore important that anyone who undergoes proctocolectomy is advised to consider eating foods rich in these vitamins and minerals to keep levels normal.

Caution must also be exercised with respect to fluid balance in a patient who has a pouch. Normal stool frequency can be four to eight times in a 24-hour period, and a great deal higher when active pouchitis is present. Patients can become dehydrated⁴⁶ and electrolytes depleted, contributing to fatigue. It can be helpful to assess fluid balance by checking the urinary sodium level, and consider the addition of electrolyte mix and antidiarrhoeal agents to reduce fluid loss. Guidance from an experienced dietitian is helpful.

Mistake 10 | Managing patients with pouch dysfunction outside a specialist centre

Restorative proctocolectomy is an operation that is designed to improve overall quality of life and remove the need for an ileostomy; however, poorly functioning pouches may impact on a patient's life in multiple ways, resulting in nutritional, psychological, physical and emotional problems. It is therefore essential that a patient who has a pouch is given access to a broad range of healthcare professionals who have the skills and experience necessary to support their various needs. If a pouch starts to function poorly, it is vital that early discussions are held with the multidisciplinary team so that all management options, including surgery, are considered.

Specialist pouch nurses, gastroenterologists, surgeons and dietitians are needed to ensure effective service delivery. Joint medical and surgical clinics can help to achieve a holistic review of a patient's quality of life and offer the full range of treatment options. As pouch surgery is not frequently performed, we recommend that, whenever possible, pouch care should be centralised to units that perform a high volume of these operations and have the healthcare support staff and infrastructure needed to manage pouch-related problems. Furthermore, patients should have a point of contact, much like an 'IBD nurse', so they can discuss problems with their pouch and be directed to the right services early.

References

- Lepistö A, Luukkonen P and Järvinen HJ. Cumulative failure rate of ileal pouch-anal anastomosis and quality of life after failure. *Dis Colon Rectum* 2002; 45: 1289–1294. doi:10.1007/s10350-004-6412-9
- Sandborn WJ. Pouchitis: definition, risk factors, frequency, natural history, classification, and public health perspective. In: Sutherland LR, McLeod RS, Noel Williams C, Martin F and Wallace JL (eds) *Trends in Inflammatory Bowel Disease Therapy* 1996. 1997; Springer Netherlands, 1997, p.51–63.
- Pardi DS and Shen B. Endoscopy in the management of patients after ileal pouch surgery for ulcerative colitis. *Endoscopy* 2008; 40: 529–533.
- Shen B. Pouchitis: What every gastroenterologist needs to know. *Clin Gastroenterol Hepatol* 2013; 11: 1538–1549.
- Sandborn WJ, Tremaine WJ, Batts KP, et al. Pouchitis after ileal pouch-anal anastomosis: a pouchitis disease activity index. *Mayo Clin Proc* 1994; 69: 409–415.
- Ben-Bassat O, Tyler AD, Xu W, et al. Ileal pouch symptoms do not correlate with inflammation of the pouch. *Clin Gastroenterol Hepatol* 2014; 12: 831–837.e2.
- van der Ploeg V, Maeda Y, Faiz OD, et al. The prevalence of chronic peri-pouch sepsis in patients treated for antibiotic-dependent or refractory primary idiopathic pouchitis. *Colorectal Dis* 2017; 19: 827–831.
- Navaneethan U and Shen B. Secondary pouchitis: Those with identifiable etiopathogenetic or triggering factors. *Am J Gastroenterol* 2010; 105: 51–64.
- Segal JP, Ding NS, Worley G, et al. Systematic review with meta-analysis: the management of chronic refractory pouchitis with an evidence-based treatment algorithm. *Aliment Pharmacol Ther* 2017; 45: 581–592.
- Annerijn van der Ploeg V, Maeda Y, Faiz OD, et al. Standardising assessment and documentation of pouchoscopy. *Frontline Gastroenterol* 2018; 9: 309–314.
- Samaan MA, Shen B, Mosli MH, et al. Reliability among central readers in the evaluation of endoscopic disease activity in pouchitis. *Gastrointest Endosc* 2018; 88: 360–369.e2.
- Segal JP, Chan H, Collins B, et al. Biofeedback in patients with ileoanal pouch dysfunction: a specialist centre experience. *Scand J Gastroenterol* 2018; 53: 665–669.
- Shen B. Diagnosis and management of postoperative ileal pouch disorders. *Clin Colon Rectal Surg* 2010; 23: 259–268.
- Shen B, Lashner BA, Bennett AE, et al. Treatment of rectal cuff inflammation (cuffitis) in patients with ulcerative colitis following restorative proctocolectomy and ileal pouch-anal anastomosis. *Am J Gastroenterol* 2004; 99: 1527–1531.
- Thompson-Fawcett MW, Mortensen NJ and Warren BF. Cuffitis and inflammatory changes in the columnar cuff, anal transitional zone, and ileal reservoir after stapled pouch-anal anastomosis. *Dis Colon Rectum* 1999; 42: 348–355.
- Thompson JS. Cuffitis: A new cause of pouch dysfunction. *Am J Gastroenterol* 1999; 94: 2007.
- Wu B, Lian L, Li Y, et al. Clinical course of cuffitis in ulcerative colitis patients with restorative proctocolectomy and ileal pouch-anal anastomoses. *Inflamm Bowel Dis* 2013; 19: 404–410.
- Phillips RK. Ileal pouch-anal anastomosis for Crohn's disease. *Gut* 1998; 43: 303–304.
- Hartley JE, Fazio VW, Remzi FH, et al. Analysis of the outcome of ileal pouch-anal anastomosis in patients with Crohn's disease. *Dis Colon Rectum* 2004; 47: 1808–1815.
- Brown CJ, Maclean AR, Cohen Z, et al. Crohn's disease and indeterminate colitis and the ileal pouch-anal anastomosis: outcomes and patterns of failure. *Dis Colon Rectum* 2005; 48: 1542–1549.
- Yu CS, Pemberton JH and Larson D. Ileal pouch-anal anastomosis in patients with indeterminate colitis: long-term results. *Dis Colon Rectum* 2000; 43: 1487–1496.
- Keighley MR. The final diagnosis in pouch patients for presumed ulcerative colitis may change to Crohn's disease: patients should be warned of the consequences. *Acta Chir Iugosl* 2000; 47: 27–31.
- Gu J, Stocchi L, Kiran RP, et al. Do clinical characteristics of de novo pouch crohns disease after restorative proctocolectomy affect ileal pouch retention? *Dis Colon Rectum* 2014; 57: 76–82.
- Panis Y, Poupard B, Nemeth J, et al. Ileal pouch/anal anastomosis for Crohn's disease. *Lancet* 1996; 347: 854–857.
- Regimbeau JM, Panis Y, Pocard M, et al. Long-term results of ileal pouch-anal anastomosis for colorectal Crohn's disease. *Dis Colon Rectum* 2001; 44: 769–778.
- Bemelman WA, Warusavitarne J, Sampietro GM, et al. ECCO-ESCP consensus on surgery for Crohn's disease. *J Crohn's Colitis* 2017; 12: 1–16.
- Deutsch AA, McLeod RS, Cullen J, et al. Results of the pelvic-pouch procedure in patients with Crohn's disease. *Dis Colon Rectum* 1991; 34: 475–477.
- Grobler SP, Hosie KB and Keighley MRB. Randomized trial of loop ileostomy in restorative proctocolectomy. *Br J Surg* 1992; 79: 903–906.
- Hyman NH, Fazio VW, Tuckson WB, et al. Consequences of ileal pouch-anal anastomosis for Crohn's colitis. *Dis Colon Rectum* 1991; 34: 653–657.
- Shen B, Fazio VW, Remzi FH, et al. Clinical features and quality of life in patients with different phenotypes of crohn's disease of the ileal pouch. *Dis Colon Rectum* 2007; 50: 1450–1459.
- Shen B, Fazio VW, Remzi FH, et al. Risk factors for clinical phenotypes of crohn's disease of the ileal pouch. *Am J Gastroenterol* 2006; 101: 2760–2768.
- Wolf JM, Achkar J-P, Lashner BA, et al. Afferent limb ulcers predict Crohn's disease in patients with ileal pouch-anal anastomosis. *Gastroenterology* 2004; 126: 1686–1691.
- Lightner AL, Fletcher JG, Pemberton JH, et al. Crohn's disease of the pouch: A true diagnosis or an oversubscribed diagnosis of exclusion? *Dis Colon Rectum* 2017; 60: 1201–1208.
- Segal JP, Poo SX, McLaughlin SD, et al. Long-term follow-up of the use of maintenance antibiotic therapy for chronic antibiotic-dependent pouchitis. *Frontline Gastroenterol* 2018; 9: 154–158.
- Kim GK. The risk of fluoroquinolone-induced tendinopathy and tendon rupture: what does the clinician need to know? *J Clin Aesthet Dermatol* 2010; 3: 49–54.
- Goolsby TA, Jakeman B and Gaynes RP. Clinical relevance of metronidazole and peripheral neuropathy: a systematic review of the literature. *Int J Antimicrob Agents* 2018; 51: 319–325.
- Seril DN and Shen B. *Clostridium difficile* infection in patients with ileal pouches. *Am J Gastroenterol* 2014; 109: 941–947.
- Herfarth HH, Long MD and Isaacs KL. Use of biologics in pouchitis. *J Clin Gastroenterol* 2015; 49: 647–654.
- Weaver KN, Gregory M, Syal G, et al. Ustekinumab is effective for the treatment of crohn's disease of the pouch in a multicenter cohort. *Inflamm Bowel Dis* 2019; 25: 767–74. doi:10.1093/ibd/izy302
- Gregory M, Weaver KN, Hoversten P, et al. Efficacy of vedolizumab for refractory pouchitis of the ileo-anal pouch: results from a multicenter US cohort. *Inflamm Bowel Dis* 2019; 25: 1569–1576.
- 'Study to compare alicaforsen with placebo in patients with pouchitis' NHS Health Research Authority <https://www.hra.nhs.uk/planning-and-improving-research/application-summaries/research-summaries/study-to-compare-alicaforsen-with-placebo-in-patients-with-pouchitis/> (accessed April 2020).
- Godny L, Maharshak N, Reshef L, et al. Fruit consumption is associated with alterations in microbial composition and lower rates of pouchitis. *J Crohn's Colitis* 2019; 13: 1265–1272.
- Ianco O, Tulchinsky H, Lusthaus M, et al. Diet of patients after pouch surgery may affect pouch inflammation. *World J Gastroenterol* 2013; 19: 6458.
- Kuisma J, Nuutinen H, Luukkonen P, et al. Long term metabolic consequences of ileal pouch-anal anastomosis for ulcerative colitis. *Am J Gastroenterol* 2001; 96: 3110–3116.
- Pastrana RJ, Torres EA, Arroyo JM, et al. Iron-deficiency anemia as presentation of pouchitis. *J Clin Gastroenterol* 2007; 41: 41–44. doi:10.1097/O1.mcg.0000012641.90477.d0
- Helavirta I, Huhtala H, Hyöty M, et al. Restorative proctocolectomy for ulcerative colitis in 1985–2009. *Scand J Surg* 2016; 105: 73–77.

Your pouchitis briefing

UEG week

- 'Therapy Update: Ulcerative colitis' session at UEG Week 2019 [<https://ueg.eu/library/session/therapy-update-ulcerative-colitis/156/2209>].
- 'Ulcerative colitis: Current management' session at UEG Week 2019 [<https://ueg.eu/library/session/ulcerative-colitis-current-management/156/2135>].

Standards and Guidelines

- Turner D, et al. Management of paediatric ulcerative colitis, part 1: Ambulatory care—an evidence-based guideline from European Crohn's and Colitis Organization and European Society of Paediatric Gastroenterology, Hepatology and Nutrition. *J Ped Gastroenterol Nutr* 2018; 67: 257–291. [<https://ueg.eu/library/management-of-paediatric-ulcerative-colitis-part-1-ambulatory-care-an-evidence-based-guideline-from-european-crohn-s-and-colitis-organization-and-european-society-of-paediatric-gastroenterology-hepatology-and-nutrition/178427>].
- Magro F, et al. Third European Evidence-based Consensus on Diagnosis and Management of Ulcerative Colitis. Part 1: Definitions, Diagnosis, Extra-intestinal Manifestations, Pregnancy, Cancer Surveillance, Surgery, and Ileo-anal Pouch Disorders. *J Crohn's Colitis* 2017; 11: 649–670. [<https://ueg.eu/library/third-european-evidence-based-consensus-on-diagnosis-and-management-of-ulcerative-colitis-part-1-definitions-diagnosis-extra-intestinal-manifestations-pregnancy-cancer-surveillance-surgery-and-ileo-anal-pouch-disorders/150756>].
- Langner C, et al. The histopathological approach to inflammatory bowel disease: a practice guide. *Virchows Arch* 2014; 464: 511–527. [<https://ueg.eu/library/the-histopathological-approach-to-inflammatory-bowel-disease-a-practice-guide/128280>].
- Van der Woude CJ, et al. The Second European Evidenced-Based Consensus on Reproduction and Pregnancy in Inflammatory Bowel Disease. *J Crohn's Colitis* 2015; 9: 107–124. [<https://ueg.eu/library/the-second-european-evidenced-based-consensus-on-reproduction-and-pregnancy-in-inflammatory-bowel-disease/125372>].
- Öresland T, et al. European evidence based consensus on surgery for ulcerative colitis. *J Crohn's Colitis* 2015; 9: 4–25 [<https://ueg.eu/library/european-evidence-based-consensus-on-surgery-for-ulcerative-colitis/125373>].