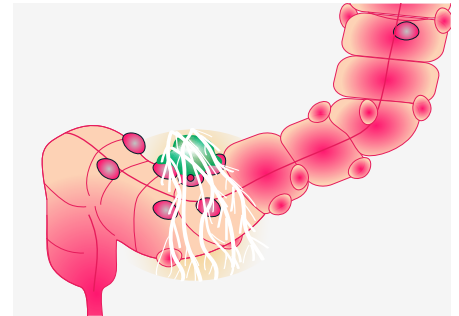


Mistakes in acute diverticulitis and how to avoid them

S.J. Rottier, A.A.W. van Geloven, W.H. Schreurs and M.A. Boermeester

Acute diverticulitis is an inflammatory complication of diverticulosis and can either be uncomplicated or complicated. Making the distinction between uncomplicated and complicated acute diverticulitis is essential because treatment strategies differ between the two. Here, we discuss 10 mistakes frequently made when managing patients with acute diverticulitis. We focus on using the correct terminology, diagnostic preference and several treatment options, such as omitting or administering antibiotics, radiological interventions and various aspects of surgery. Acute diverticulitis is an important topic because its incidence is rising worldwide and it is becoming a considerable burden on healthcare systems. Most of the discussion included here is evidence-based, supplemented with many years' combined clinical experience where evidence is lacking.



Mistake 1 Using incorrect terminology

A variety in terminology is used in the diverticular literature, which can lead to misinterpretation and often makes any recommendations made unsuitable for use in daily practice. A diverticulum (pl. diverticula) is a small outpouching from the lumen of the colon that results from herniation of the colon wall at the weakest anatomic location, which is where the terminal branches of the colonic arteries (the vasa recta) penetrate.^{1,2} Diverticulosis means that a patient has one or more diverticula but no clinical symptoms whatsoever, which equates to

them being described as asymptomatic. Most people do not know whether they have diverticula, because they only see a doctor when they are symptomatic. Another way diverticula are diagnosed is during an abdominal CT or colonoscopy, usually being identified as an additional finding.

Acute diverticulitis occurs when a diverticulum becomes inflamed, and this inflammatory complication of diverticulosis can be uncomplicated or complicated (figure 1). Uncomplicated diverticulitis describes peridiverticular inflammation of the colon, whereas complicated diverticulitis

encompasses diverticular abscess formation, perforation, obstruction or fistula formation. Nowadays, the modified Hinchey classification, which includes CT imaging, is used in both the literature and daily practice to distinguish between uncomplicated (Hinchey Ia) and complicated (> Hinchey Ib) diverticulitis (table 1).^{3,4}

So, patients with diverticulosis are asymptomatic and patients with acute diverticulitis are symptomatic. As there is no clear way to diagnose so-called symptomatic uncomplicated diverticular disease (SUDD), the terms SUDD and diverticular disease should be avoided. When this terminology is used in literature, it is not clear whether the information is about diverticulosis or diverticulitis, since this is often not explained. Moreover, it is doubtful whether SUDD can be reliably distinguished from irritable bowel syndrome (IBS) complaints that overlap with symptomatic diverticulosis.

Mistake 2 Using dietary restrictions to treat and prevent diverticulitis

For many years diet has been mentioned as a possible risk factor for the development of diverticula and acute diverticulitis.⁵ Dietary restrictions—ranging from nil-by-mouth to liquid diets and low- or high-fibre diets—have often been part of the treatment of acute diverticulitis or, when the acute phase has passed, as a preventive treatment. Two studies have shown that an unrestricted diet does not lead to an increase of diverticular complications in patients with acute diverticulitis.^{6,7} One, a prospective

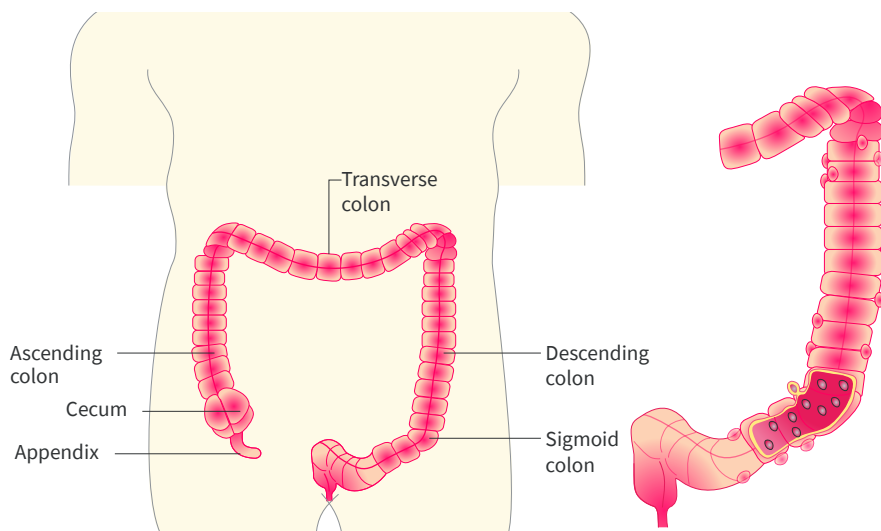


Figure 1 | Diverticulosis of the descending and sigmoid part of the colon. Part of the colon has a thicker wall caused by inflammation and infection known as diverticulitis.

© UEG 2019 Rottier, van Geloven, Schreurs and Boermeester.

Cite this article as: Rottier SJ, et al. Mistakes in acute diverticulitis and how to avoid them. *UEG Education* 2019; 19: 31–35.

Simone J. Rottier is an MD working in the Department of Surgery at Amsterdam University Medical Centers, Amsterdam, The Netherlands. **Anna A.W. van Geloven** is a gastrointestinal surgeon at

the Department of Surgery at Tergooi, Hilversum, The Netherlands. **W. Hermien Schreurs** is a lung and gastrointestinal surgeon in the Department of Surgery, Northwest Clinics, Alkmaar/Den Helder, The Netherlands. **Marja A. Boermeester** is a professor of surgery and a clinical epidemiologist in the Department of Surgery at Amsterdam University Medical Centers, Amsterdam, The Netherlands.

Images courtesy of: S.J. Rottier, A.A.W. van Geloven, W.H. Schreurs and M.A. Boermeester. **Illustrations:** J. Shadwell.

Correspondence to: m.a.boermeester@amsterdamumc.nl

Conflicts of interest: The authors declare there are no conflicts of interest.

Published online: December 20, 2019.

Stage	Description
0	Mild clinical diverticulitis (no clear signs on imaging)
Ia	Confined pericolic inflammation or phlegmon
Ib	Pericolic or mesocolic abscess
II	Pelvic, distant intra-abdominal or retroperitoneal abscess
III	Generalized purulent peritonitis
IV	Generalized faecal peritonitis

Table 1 | Modified Hinchey classification of acute diverticulitis.⁴

cohort study, included 86 patients with uncomplicated diverticulitis who received an unrestricted diet; about 8% were readmitted for pain management but without developing complicated diverticulitis.⁶ These results are in line with what has been reported as the complication rate in patients with an episode of initially uncomplicated diverticulitis.⁸

Although a high-fibre diet may be recommended for general health purposes, there is little evidence that it benefits recovery during acute diverticulitis episodes or prevents recurrent episodes. The quality of this evidence is low, but in the absence of evidence favouring dietary restriction, we believe that an unrestricted diet is justifiable for patients who have acute (uncomplicated) diverticulitis. Also, the negative effects of malnutrition need to be avoided, since it can prolong hospital stay for patients who are admitted.

Mistake 3 Thinking all large abscesses must be treated by (emergency) surgery

Treatment of abdominal abscesses caused by acute diverticulitis (figure 2) has changed considerably over the years. Patients can now be treated conservatively with antibiotics, undergo percutaneous drainage, receive a combination of antibiotics and percutaneous drainage, or undergo (emergency) surgery.

With the improvement of CT imaging and CT- or US-guided interventions, percutaneous drainage has become a frequently performed procedure for patients with diverticular abscesses. A systematic review with meta-analysis from 2016 included 42 articles and focused on patients with diverticular abscesses who were treated nonoperatively (either with antibiotics or percutaneous drainage).⁹ The primary outcome of the systematic review was therapy failure, defined as emergency surgery, readmission or

mortality within 30 days of initial treatment, residual abscess at follow-up or persistent symptoms. The results showed a pooled failure rate of approximately 20%.

Since then, a multicentre retrospective cohort study has been published that focused on the outcome of nonsurgical treatment for patients with a CT-diagnosed diverticular abscess (modified Hinchey Ib or II; table 1).¹⁰ Treatment with antibiotics only was compared with treatment with a combination of antibiotics and percutaneous drainage—no difference in short-term treatment failure, the need for emergency surgery or long-term surgery was found between the two groups. Treatment failure in this study was defined as a composite outcome of complications (perforation, colonic obstruction and fistula formation), readmissions, persistent diverticulitis, emergency surgery, death, or need for percutaneous drainage in the no percutaneous drainage group. Short-term treatment failure in Hinchey Ib patients was 22.3% for antibiotic treatment only versus 33.0% in patients who received antibiotics plus additional percutaneous drainage ($P=0.359$). Results for Hinchey II patients were similar, with a short-term failure of 25.9% for patients receiving antibiotics only versus 36.0% for patients receiving antibiotics with additional percutaneous drainage ($P=0.149$).¹⁰ Abscesses >5 cm in diameter were associated with the need for surgery at short-term follow-up ($P=0.036$).

In our opinion, the size and location of an abscess, and whether or not it has an enhancing wall, determines the therapy of choice and the possibility of performing percutaneous drainage. For patients who have an abscess <3cm, treatment with antibiotics only is appropriate. Although the role of percutaneous drainage of abscesses in acute diverticulitis is not completely clear, we think it may be considered in patients who have an abscess >3 cm. In case of failure of percutaneous drainage and/or antibiotics, and in a critically ill or deteriorating patient (emergency), repeating

abdominal CT followed by emergency surgery may be necessary.

Mistake 4 Overlooking the need for the appropriate imaging evaluation

Since the treatment of acute diverticulitis has changed dramatically over the years, the role of imaging diagnostics has become more important. US and CT are now widely available and frequently used in the emergency department to aid the rapid and correct diagnosis of acute diverticulitis and to determine its severity.

Classifying a patient correctly and without delay as having uncomplicated or complicated diverticulitis is essential because it influences treatment choice; in most cases, acute uncomplicated diverticulitis can be treated conservatively. Although a US diagnosis of acute diverticulitis is reliable, US is less accurate than CT for distinguishing uncomplicated from complicated diverticulitis (figure 3).¹¹ Missing complicated diverticulitis can have severe clinical implications. Therefore, especially in clinically ill patients who have failure of one or more organs other than the digestive tract, we advise performing an abdominal CT to confirm the diagnosis and to confirm or exclude complications. In suspected uncomplicated diverticulitis, starting with US is advised.¹⁰ Moreover, CT has a higher diagnostic accuracy compared with US for detecting an alternative diagnosis, which could obviously influence treatment choice.^{12,13}

Mistake 5 Assuming pericolic extraluminal air in left-sided acute colonic diverticulitis must be treated with emergency surgery

Pericolic extraluminal air is seen on a CT scan in about 15% of patients with acute diverticulitis and is often wrongly associated with the need for emergency surgical intervention.^{14,15} The Hinchey

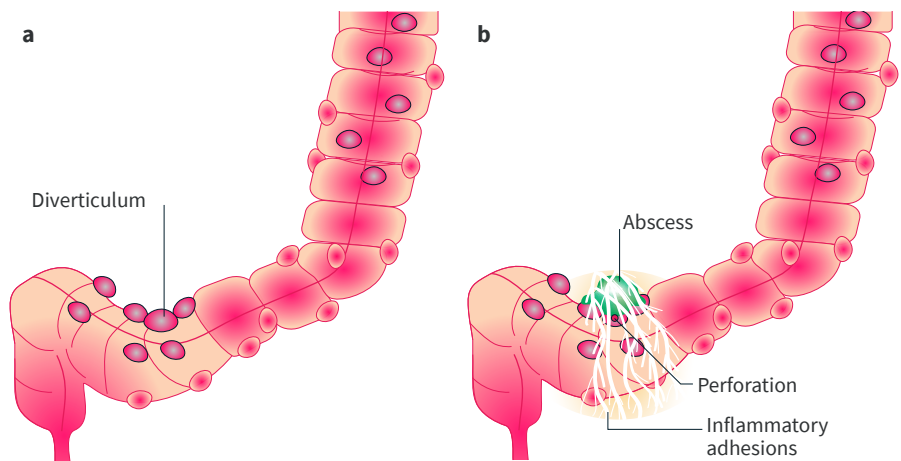


Figure 2 | Acute diverticulitis. a | Uncomplicated diverticulitis with peridiverticular inflammation of the colon. b | Inflammatory adhesions, abscess formation and perforation indicate the presence of complicated diverticulitis, as do obstruction and fistula formation.

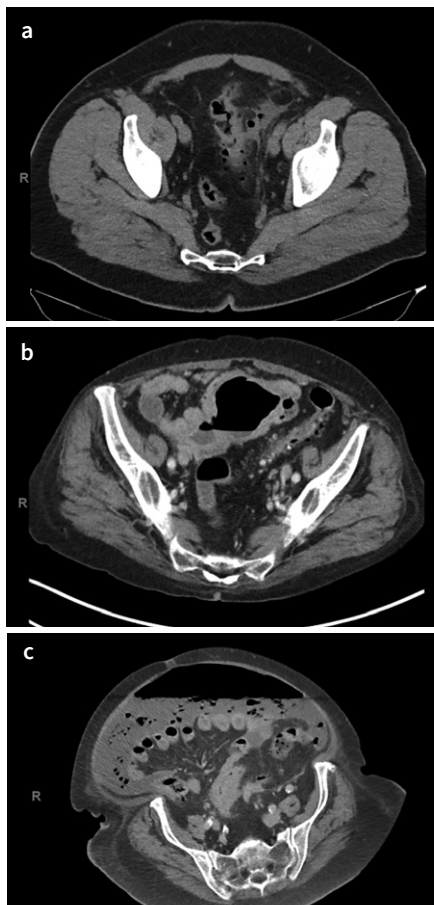


Figure 3 | Abdominal CT scans of diverticulitis. **a** | Acute diverticulitis with pericolic extraluminal air. **b** | Diverticulitis with abscess formation (Hinchey II). **c** | Perforated diverticulitis with faecal peritonitis (Hinchey IV).

classification is a radiological classification frequently used to help determine which type of treatment a patient should receive; however, pericolic air is not included in the Hinchey classification and evidence on the natural course of pericolic extraluminal air visualized by CT is scarce.

A systematic review and meta-analysis, including eight studies, evaluated the need for emergency surgery and the need for percutaneous abscess drainage during the initial course of acute diverticulitis.¹⁶ In six of the eight studies, all patients were treated with antibiotics, in one study only some patients, and in one study no information was supplied about the use of antibiotics. An initial 94% success rate (no need for further treatment) was found for nonoperative treatment of patients with isolated pericolic extraluminal air caused by left-sided acute diverticulitis. This finding is in line with the tendency to treat patients who have acute diverticulitis more conservatively, in this case with antibiotics instead of emergency surgery.

A retrospective observational multicentre study of conservative treatment was performed comprising 91 patients with perforated

diverticulitis, initially without abscess or peritonitis but with free pneumoperitoneum.¹⁷ In 29 of the 91 patients (31.9%), conservative (antibiotic) treatment failed, with failure defined as the formation of an abscess >4 cm or the occurrence of peritonitis. Among the 29 patients whose treatment failed, 24 had a pneumoperitoneum diameter >5 mm. Indeed, risk factors for failure of conservative treatment are tachycardia, CRP levels >150mg/mL, pericolic air with a volume of >5 mm and peritoneal fluid in the pouch of Douglas.¹⁷

The systematic review previously described¹⁶ excluded patients with pneumoperitoneum, defined as the presence of gas within the peritoneal cavity, which explains the difference in results between the systematic review and the retrospective series. The description of “pericolic extraluminal air” is crucial, because patients with pericolic extraluminal air caused by acute diverticulitis can usually be carefully observed with frequent physical examination, laboratory follow-up, intravenous antibiotic treatment, and in case of deterioration repeat abdominal CT.

In conclusion, we believe that the vast majority of patients with isolated pericolic extraluminal air caused by left-sided acute diverticulitis do not need an emergency intervention. In case of failure of conservative treatment, characterized by progressive disease, repeat CT is needed.

Mistake 6 Routine prescription of antibiotics for patients with acute uncomplicated diverticulitis

Probably one of the most frequently made mistakes when treating patients with acute diverticulitis is the routine prescription of antibiotics for those whose diverticulitis is uncomplicated. Certainly, uncomplicated diverticulitis has been treated with antibiotics for decades, even though this is not supported by the literature.

The multicentre randomized DIABOLO trial has shown that observational treatment without antibiotics does not prolong the time to full recovery of patients with CT-diagnosed left-sided uncomplicated diverticulitis.¹⁸ Full recovery was evaluated by the following criteria: a normal diet, temperature <38°C, VAS pain score <4 (no need for daily pain medication), discharge from hospital and resumption of pre-illness working activities as assessed by a daily patient diary. Similarly, the multicentre randomized AVOD trial from Scandinavia, which also included patients with CT-diagnosed left-sided uncomplicated diverticulitis, found that antibiotic treatment neither accelerated recovery nor prevented complications or recurrence.¹⁹

We believe that patients who have acute uncomplicated diverticulitis should be treated without antibiotics and that only in specific cases, such as immunocompromised patients, should

antibiotic treatment be chosen. The results of the two RCTs discussed above have been combined to assess the long-term effects of omitting antibiotics in this specific patient population.²⁰ After a follow-up of 24 months, treatment of acute uncomplicated diverticulitis without antibiotics did not result in more complicated diverticulitis, recurrent diverticulitis or sigmoid resections than treatment with antibiotics.

Mistake 7 Routine hospital admission for acute uncomplicated diverticulitis

As we see no need to routinely prescribe antibiotics for the treatment of acute uncomplicated diverticulitis (see mistake 6), it follows that there is no definite need to admit these patients to hospital for administration of intravenous antibiotics. This leads to new treatment options for this specific population—outpatient treatment.

A recently performed systematic review and meta-analysis included more than 2,000 patients with uncomplicated diverticulitis who received outpatient treatment. Only 7% of patients had to be admitted to hospital, 0.2% needed to undergo emergency surgery and another 0.2% underwent percutaneous abscess drainage.²¹ These results are supported by another study that analysed more than 1,000 patients with CT-proven left-sided acute uncomplicated diverticulitis, to find possible risk factors for the developing a complicated course.⁸ Less than 5% of all patients developed complicated diverticulitis, and most of them within the 10 days of their initial diagnosis. Patients with a systemic comorbidity, defined as American Society of Anesthesiologists (ASA) 3 or 4, who vomited, had symptoms for more than 5 days or an elevated CRP level above 140 mg/L at initial presentation, had a higher risk of developing a complicated course of initially uncomplicated diverticulitis.

With these risk factors in mind, and targeting patients with sufficient mental capacity to understand the possible outcomes and what they need to be aware of, most patients with CT-proven acute uncomplicated diverticulitis seem suitable for outpatient treatment. Outpatient treatment not only benefits patients, who usually prefer to recuperate at home and not to be admitted to hospital for observation, it may also help to reduce healthcare costs.

Mistake 8 Thinking that more aggressive treatment is indicated for young patients

In the past, diverticulitis was a disease associated with elderly patients; however, acute diverticulitis also affects many young patients. Some believe that young patients have a more severe disease course and a higher recurrence rate than elderly patients. The current Dutch national guideline for acute diverticulitis²² addressed whether young

patients require a different (more aggressive) therapy than elderly patients. We have performed a systematic review (unpublished results) to answer this question; a total of 27 studies were included, half of them only included cases of left-sided diverticulitis and 20 of 27 studies were conducted in Europe. The data from 20 studies that reported the stage of diverticulitis at presentation were pooled, resulting in analysis of 7,477 patients. There was substantial heterogeneity among the studies and the level of evidence was low. The results showed that young age was not associated with an increased risk of complicated diverticulitis or the need for emergency surgery or percutaneous drainage. Twelve studies mentioned the recurrence rate, whereas 3 of 12 studies took into account the length of follow-up, making them more reliable in terms of drawing any conclusions. Young age was also not associated with an increased risk of recurrence of diverticulitis.

Although the evidence is not that strong, there is no evidence that young patients should be treated any differently to elderly patients—young patients do not suffer from a more severe disease course or have a higher risk of recurrent diverticulitis. However, it is important to keep in mind that younger patients have different demands because many of them work or participate in sporting activities. The decision on whether or not to perform elective surgery for recurrent disease or chronic complaints is influenced by such individual factors, so lower thresholds for surgery in younger patients may lead to a higher proportion undergoing elective surgery.

Mistake 9 Assuming routine colonoscopy is always indicated after a first episode of acute diverticulitis

In the past, routine colonoscopy was traditionally recommended after a first episode of acute diverticulitis to rule out coexisting malignancy, but at that time acute diverticulitis was often a clinical diagnosis. Since CT imaging has improved greatly over the years and is used more regularly to diagnose diverticulitis, the question of whether routine colonoscopy after an episode of acute diverticulitis is still necessary has come up for debate.^{12,13} However, most guidelines have not been updated and still recommend routine colonoscopy after acute diverticulitis, and many clinicians still follow these guidelines.²³⁻²⁸

A 2019 systematic review and meta-analysis has altered recommendations concerning the follow-up after acute diverticulitis.²⁹ An important conclusion of the meta-analysis was that acute diverticulitis does not increase the future risk of colorectal carcinoma. Moreover, this systematic review also shows that the risk of colorectal carcinoma being present at the initial

presentation is comparable among patients with CT-diagnosed acute diverticulitis versus asymptomatic controls. Older studies that included patients who had a clinical rather than CT diagnosis of acute diverticulitis have found an association with colorectal carcinoma within the first year of presentation. This association is probably due to misdiagnosis, because the development of carcinoma from a dysplastic or premalignant lesion takes longer than 1 year.

In general, the potential gain of performing colonoscopy, such as detection of an unsuspected malignancy, should be weighed against its potential disadvantages, such as the risk of perforation, patient discomfort and the burden of healthcare utilisation. Routine colonoscopy may be omitted in patients with an episode of CT-verified uncomplicated diverticulitis, and they can be referred back to the colorectal cancer screening program. However, routine colonoscopy should remain the protocol for patients with complicated diverticulitis treated without resection and those with ongoing complaints (pain and/or fever and/or changed stools) after CT-verified uncomplicated diverticulitis. Such a colonoscopy should be performed at least 6 weeks after acute disease.

Mistake 10 Performing a Hartmann’s procedure instead of a primary anastomosis for perforated diverticulitis

When a patient is diagnosed with perforated diverticulitis and has a purulent (Hinchey III) or faecal (Hinchey IV) peritonitis, emergency surgery is indicated. Many surgeons still believe that a Hartmann’s procedure—surgical resection of the affected part of the colon followed by construction of an end colostomy (Figure 4a)—is the best treatment. However, three randomized controlled trials (RCTs) have compared sigmoid resection with a primary anastomosis (Figure 4b) with a Hartmann’s procedure.³⁰⁻³² Morbidity and mortality are comparable for sigmoid resection with primary anastomosis and sigmoid resection

with end colostomy. Primary anastomosis results in a lower stoma rate at long-term follow-up. When choosing a stoma in case of a primary anastomosis a diverting loop ileostomy is usually performed, which is less difficult to reverse. Thereby, for sigmoid resection and primary anastomosis, the number of permanent stomas is lower compared with a Hartmann’s procedure. Of critical note, however, is that all three clinical trials were prematurely terminated and their study designs were not optimal.

Another RCT published in 2019 compared both surgical interventions for perforated diverticulitis (the LADIES trial), and provides strong evidence that primary resection with anastomosis is a more appropriate treatment than a Hartmann’s procedure for patients with acute diverticulitis with purulent or faecal peritonitis.³³ This preference is related to a better 12-month stoma-free survival and a reduced risk of morbidity related to stoma reversal, which adds up to comparable short-term morbidity and mortality but with a lower proportion of stomas being present. This recommendation applies to patients who are haemodynamically stable and immunocompetent.

Finally, a large national retrospective cohort study comprising 67,721 patients who underwent concurrent faecal diversion generated different results.³⁴ Indeed, in this study patients who underwent end colostomy (65,084 of 67,721 patients, 96.1%), had a lower risk for complications compared with patients who underwent anastomosis and ileostomy (2,637 of 67,721 patients, 3.9%); 23.3 % versus 32.1% ($P < 0.001$). The in-hospital mortality rate was higher in the group undergoing primary anastomosis and diversion; 16.0% versus 6.4% ($P = 0.001$). However, due to the retrospective nature of this study selection bias is a serious limitation, as a mere 3.9% of patients received a primary anastomosis. Moreover, we have no knowledge about the experience and subspecialty of the surgeons performing the operations in these 67,721 patients. At present, we should, therefore, rely on the data from the

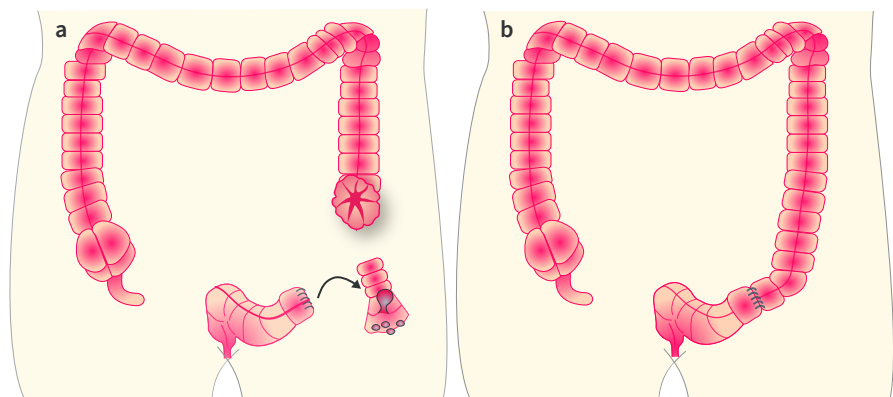


Figure 4 | Surgical treatment of diverticulitis. a | Hartmann’s procedure, a surgical resection of the affected part of the colon and construction of an end colostomy. b | Sigmoid resection and primary anastomosis.

four RCTs that have been conducted and have come to similar conclusions,^{30–33} rather than on contradictory data from a retrospective cohort study.³⁴

Based on the current evidence, the clinical condition of the patient and the expertise of the surgeon, a primary resection with anastomosis with or without a diverting ileostomy may be preferred over a Hartmann's procedure for patients with perforated diverticulitis. Moreover, in general, patients do not like the idea of having a colostomy, and for too many patients the temporary stoma becomes a permanent stoma, which results in disappointment and lower quality of life. In conclusion, in haemodynamically stable patients a primary anastomosis with or without diverting loop ileostomy can be performed. The choice of a diverting ileostomy depends on many local and patient-related factors, and is left to the discretion of the surgeon.

References

- Painter NS. Diverticular disease of the colon. *Br Med J* 1968; 3: 475–479.
- Stollman N and Raskin JB. Diverticular disease of the colon. *Lancet* 2004; 363: 631–639.
- Hinchey EJ, et al. Treatment of perforated diverticular disease of the colon. *Adv Surg* 1978; 12: 85–109.
- Wasvary H, et al. Same hospitalization resection for acute diverticulitis. *Am Surg* 1999; 65: 632–635.
- Burkitt DP, et al. Effect of dietary fibre on stools and the transit-times, and its role in the causation of disease. *Lancet* 1972; 2: 1408–1412.
- Stam MA, et al. An unrestricted diet for uncomplicated diverticulitis is safe: results of a prospective diverticulitis diet study. *Colorectal Dis* 2017; 19: 372–377.
- van de Wall BJ, et al. Dietary restrictions for acute diverticulitis: evidence-based or expert opinion? *Int J Colorectal Dis* 2013; 28: 1287–1293.
- Rottier SJ, et al. Complicated disease course in initially computed tomography-proven uncomplicated acute diverticulitis. *Surg Infect (Larchmt)* Epub ahead of print (August 14 2019). doi: 10.1089/sur.2018.289.
- Gregersen R, et al. Treatment of patients with acute colonic diverticulitis complicated by abscess formation: A systematic review. *Int J Surg* 2016; 35: 201–208.
- Lambrichts DPV, et al. Multicentre study of non-surgical management of diverticulitis with abscess formation. *Br J Surg* 2019; 106: 458–466.
- Nielsen K, et al. The limited role of ultrasound in the diagnostic process of colonic diverticulitis. *World J Surg* 2014; 38: 1814–1818.
- Lameris W, et al. Graded compression ultrasonography and computed tomography in acute colonic diverticulitis: meta-analysis of test accuracy. *Eur Radiol* 2008; 18: 2498–2511.
- van Randen A, et al. A comparison of the accuracy of ultrasound and computed tomography in common diagnoses causing acute abdominal pain. *Eur Radiol* 2011; 21: 1535–1545.
- Bridoux V, et al. Elective operation after acute complicated diverticulitis: is it still mandatory? *World J Gastroenterol* 2014; 20: 8166–8172.
- Sallinen VJ, et al. Nonoperative management of perforated diverticulitis with extraluminal air is safe and effective in selected patients. *Dis Colon Rectum* 2014; 57: 875–881.
- van Dijk ST, et al. A systematic review of pericolic extraluminal air in left-sided acute colonic diverticulitis. *Surg Infect (Larchmt)* 2018; 19: 362–368.
- Colas PA, et al. Failure of conservative treatment of acute diverticulitis with extradigestive air. *World J Surg* 2017; 41: 1890–1895.
- Daniels L, et al. Randomized clinical trial of observational versus antibiotic treatment for a first episode of CT-proven uncomplicated acute diverticulitis. *Br J Surg* 2017; 104: 52–61.
- Chabok A, et al. Randomized clinical trial of antibiotics in acute uncomplicated diverticulitis. *Br J Surg*. 2012; 99: 532–539.
- van Dijk ST, et al. Long-term effects of omitting antibiotics in uncomplicated acute diverticulitis. *Am J Gastroenterol* 2018; 113: 1045–1052.
- van Dijk ST, et al. A systematic review and meta-analysis of outpatient treatment for acute diverticulitis. *Int J Colorectal Dis* 2018; 33: 505–512.
- de Boer MGJ, et al. The Dutch national guideline 'Acute Diverticulitis', (2018, accessed 28 November 2019; in Dutch).
- Andersen JC, et al. Danish national guidelines for treatment of diverticular disease. *Dan Med J* 2012; 59: C4453.
- Binda GA, et al. Practice parameters for the treatment of colonic diverticular disease: Italian Society of Colon and Rectal Surgery (SICCR) guidelines. *Tech Coloproctol* 2015; 19: 615–626.
- Feingold D, et al. Practice parameters for the treatment of sigmoid diverticulitis. *Dis Colon Rectum* 2014; 57: 284–294.
- Kruis W, et al. Diverticular disease: Guidelines of the German Society for Gastroenterology, Digestive and Metabolic Diseases and the German Society for General and Visceral Surgery. *Digestion* 2014; 90: 190–207.
- Stollman N, et al. American Gastroenterological Association Institute guideline on the management of acute diverticulitis. *Gastroenterology* 2015; 149: 1944–1949.
- Wilkins T, et al. Diagnosis and management of acute diverticulitis. *Am Fam Physician* 2013; 87: 612–620.
- Rottier SJ, et al. Meta-analysis of the role of colonoscopy after an episode of left-sided acute diverticulitis. *Br J Surg* 2019; 106: 988–997.
- Binda GA, et al. Primary anastomosis vs nonrestorative resection for perforated diverticulitis with peritonitis: a prematurely terminated randomized controlled trial. *Colorectal Dis* 2012; 14: 1403–1410.
- Bridoux V, et al. Hartmann's procedure or primary anastomosis for generalized peritonitis due to perforated diverticulitis: a prospective multicenter randomized trial (DIVERTI). *J Am Coll Surg* 2017; 225: 798–805.
- Oberkofler CE, et al. A multicenter randomized clinical trial of primary anastomosis or Hartmann's procedure for perforated left colonic diverticulitis with purulent or fecal peritonitis. *Ann Surg* 2012; 256: 819–826.
- Lambrichts DPV, et al. Hartmann's procedure versus sigmoidectomy with primary anastomosis for perforated diverticulitis with purulent or faecal peritonitis (LADIES): a multicentre, parallel-group, randomised, open-label, superiority trial. *Lancet Gastroenterol Hepatol* 2019; 4: 599–610.
- Cauley CE, et al. Use of primary anastomosis with diverting ileostomy in patients with acute diverticulitis requiring urgent operative intervention. *Dis Colon Rectum* 2018; 61: 586–592.

Your diverticulitis briefing

UEG Week

- 'Update on diverticulitis' session at UEG Week 2019 [https://www.ueg.eu/education/session-files/?session=2122&conference=156].
- 'Symptomatic diverticular disease' presentation in the 'Therapy update in functional gastrointestinal disorders' session at UEG Week 2018 [https://www.ueg.eu/education/document/symptomatic-diverticular-disease/183879/].
- 'Diverticulitis' presentation in 'Therapy update: Practical algorithms in various GI disorders' session at UEG week 2019 [https://www.ueg.eu/education/document/diverticulitis/211467/].
- 'Update on diverticular disease' session at 25th UEG Week 2017 [https://www.ueg.eu/education/session-files/?session=1897&conference=149].
- 'Trial presentation: Randomised clinical trial of observational versus antibiotic treatment for a first episode of CT-proven uncomplicated acute diverticulitis' presentation in the 'Clinical Trials revisited: Antibiotics in lower GI diseases – Should they be used?' session at 25th UEG Week 2017 [https://www.ueg.eu/education/document/trial-presentation-randomised-clinical-trial-of-observational-versus-antibiotic-treatment-for-a-first-episode-of-ct-proven-uncomplicated-acute-diverticulitis/155576/].
- 'Diverticular disease: Medical and surgical management' session at UEG Week 2016

[https://www.ueg.eu/education/session-files/?session=1568&conference=144].

Standards & Guidelines

- Trifan A-V, et al. Diagnosis and treatment of colonic diverticular disease: position paper of the Romanian Society of Gastroenterology and Hepatology. *J Gastrointestin Liver Dis* 2018; 27: 449–457 [https://www.ueg.eu/education/document/diagnosis-and-treatment-of-colonic-diverticular-disease-position-paper-of-the-romanian-society-of-gastroenterology-and-hepatology/203028/].
- Kruis W, et al. Diverticular disease: Guidelines of the German Society for Gastroenterology, Digestive and Metabolic Diseases and the German Society for General and Visceral Surgery. *Digestion* 2014; 90: 190–207 [https://www.karger.com/Article/Abstract/367625].
- Andersen JC, et al. Danish national guidelines for treatment of diverticular disease. *Dan Med J* 2012; 59: C4453 [https://ugeskriftet.dk/dmj/danish-national-guidelines-treatment-diverticular-disease].
- Binda GA, et al. Practice parameters for the treatment of colonic diverticular disease: Italian Society of Colon and Rectal Surgery (SICCR) guidelines. *Tech Coloproctol* 2015; 19: 615–626 [https://link.springer.com/article/10.1007%2Fs10151-015-1370-x].